An Evaluation of the Diagnostic and Prognostic Significance of $p16^{INK4a}/p21^{WAF1/Cip1}$ Immunostaining in Squamous Intraepithelial Lesions of the Uterine Cervix Using Liquid-Based Cytology Specimens

Katsunari Ishida, C.T.,[1,2] Asuka Araki, M.D., Ph.D.,[3] Masayuki Kobayashi, M.D., Ph.D.,[4,5] Kiyomi Taniyama, M.D., Ph.D.,[6] Toru Nabika, M.D., Ph.D.,[2*] and Makoto Nagasaki, M.D., Ph.D.[1]

Human papillomavirus (HPV) infection frequently causes squamous intraepithelial lesions (SIL) of the uterine cervix and consequently gives rise to squamous cell carcinoma. It is therefore important to identify cases that potentially develop higher grades of SIL at an early stage of the disease. In this study, we thus investigated whether immunocytochemistry for $p21^{WAF1/Cip1}$ and $p16^{INK4a}$ could be applicable in the diagnosis and the prognostic prediction of SIL in combination with genomic analyses of HPV. The genomic analysis of high-risk HPV (hrHPV), which was done by reversed dot blotting and by in situ hybridization, and immunocytochemistry were performed on liquid-based cytological specimens. A cross-sectional study comprising 145 cases of NILM, ASC-US, LSIL, and HSIL indicated that the incidence of the positive cases for $p16^{INK4a}$ and $p21^{WAF1/Cip1}$ and hrHPV increased with the grade of SIL. A double positive status for $p16^{INK4a}$ and $p21^{WAF1/Cip1}$ was a significant discriminator between HSIL and LSIL/NILM, even when applied in conjunction with the genomic test for hrHPV ($P = 0.006$ by logistic regression analysis). However, a prospective study employing 61 NILM/ASC-US cases, revealed that the $p16^{INK4a}/p21^{WAF1/Cip1}$ immunostaining was not a significant predictor for the progression of SIL, whereas the cytological diagnosis (NILM vs. ASC-US) and the infection status of hrHPV conferred significant effects on the prognosis. Immunostaining of $p16^{INK4a}$ and $p21^{WAF1/Cip1}$ provides additional information on the cytological diagnosis of SIL. A further analysis using a larger population is warranted to obtain a conclusive result regarding the prognostic significance of $p16^{INK4a}/p21^{WAF1/Cip1}$ immunocytochemistry in the diagnosis of SIL. Diagn. Cytopathol. 2014;42:125–133. © 2013 Wiley Periodicals, Inc.

Key Words: cervical intraepithelial neoplasia; $p16^{INK4a}$; $p21^{WAF}$; human papillomavirus; liquid-based cytological specimen

Human papillomavirus (HPV) has a number of different genotypes, of which high-risk genotypes such as type 16 and 18 are known to be responsible for cervical cancer.[1] Although most HPV infections are eliminated by the immune system of the hosts, 10–20% of the infected hosts develop cervical intraepithelial neoplasia (CIN) and invasive carcinoma progressively.[2] Therefore, it is of clinical importance to identify cases that would develop high-grade CIN among the HPV-positive hosts at an earlier stage of infection.

[1]Department of Clinical Laboratory, The National Hospital Organization Hamada Medical Center, Hamada, Japan
[2]Department of Functional Pathology, Shimane University School of Medicine, Izumo, Japan
[3]Department of Organ Pathology, Shimane University School of Medicine, Izumo, Japan
[4]Department of Obstetrics and Gynecology, The National Hospital Organization Hamada Medical Center, Hamada, Japan
[5]Institute for Clinical Research, The National Hospital Organization Hamada Medical Center, Hamada, Japan
[6]Institute for Clinical Research, The National Hospital Organization Kure Medical Center and Chugoku Cancer Center, Kure, Japan
*Correspondence to: Toru Nabika, MD., PHD., Department of Functional Pathology, Shimane University School of Medicine, Izumo 693-8501, Japan. E-mail: nabika@med.shimane-u.ac.jp
Received 30 August 2012; Accepted 4 April 2013
DOI: 10.1002/dc.23008
Published online 11 June 2013 in Wiley Online Library (wileyonlinelibrary.com).

© 2013 WILEY PERIODICALS, INC.

The cytological examination was widely used as a less-invasive screening method to identify CIN or squamous intra-epithelial lesion (SIL, used for cytological changes indicating the existence of CIN). Although the cytological examination is accepted as reliable method for the identification of CIN or SIL, it would be more useful if it was applicable to the purpose stated above, i.e., for the detection of cases with a high probability of developing higher grade CIN/SIL.

A number of studies pointed out that the disturbance of the cell cycle regulation by the RB-cyclin system was the key in cervical carcinogenesis; E6 and E7 proteins of HPV inhibit the functions of the RB and p53 proteins, and thus promote cellular proliferation.[3,4] In this process, $p16^{INK4a}$ (hereafter abbreviated as p16), a cyclin-dependent kinase (CDK) inhibitor, was shown to accumulate in the epithelium infected with HPV, and, thus, immunohistochemistry of p16 has been thought useful in the diagnosis of SIL and CIN.[5–8] Another CDK inhibitor, $p21^{WAF1/Cip1}$ (p21) was induced by the activation of p53, and was known to play important roles in anti-oncogenesis.[9–11] Although this CDK inhibitor was expected to be another useful marker for SIL/CIN, the applicability of p21 in the cytological diagnosis was not fully evaluated.

Molecular analyses clearly showed that the integration of the HPV DNA into the host genome was essential for the significant induction of the E6/E7 protein.[12–15] As a result, high-grade SIL/CIN showed a high incidence of integrated HPV DNA in the genome of the cervical epithelium when examined by in situ hybridization (ISH).[16–18] The identification of the integrated HPV genome by ISH may therefore be an excellent screening method to identify cases with high-risk SIL in the cytological examination.[19,20] However, such genomic or molecular analyses are labor-intensive and costly, thus hampering its application in the routine cytological examination. In contrast, immunocytochemistry is more feasible to perform in the routine examination.

Therefore, in this study, we evaluated the utility of the immunocytochemical test for p16 and p21 in the diagnosis of SIL. We tested whether p16/p21 immunostaining could be substituted for the genomic examinations of HPV or whether the immunocytochemical test gave additional information on the genomic analyses of HPV.

Materials and Methods

Subjects

A hundred and forty-nine cytological samples were collected from consecutive new patients who visited the Department of Obstetrics and Gynecology of the National Hospital Organization (NHO) Hamada Medical Center between May, 2008 and March, 2011. Patients with the history of cervical cancer and of the exposure to diethylstilbestrol in utero as well as immunocompromised patients were excluded from the study. In addition, any cases diagnosed as "unsatisfactory for evaluation" according to the Bethesda System were excluded. The cytological specimens were obtained with a bloom brush. After the smear samples were prepared, the brush was washed in Thinprep PreservCyt Solution (Hologic Inc, Bedford, MA) to recover and fix the residual cells.[21] These cells were then used in the liquid-based cytology preparation for immunocytochemistry, as well as for ISH and the reversed dot blotting for HPV genotyping. A cytological diagnosis was made using smear specimens according to the Bethesda system by four experienced cytotechnologists and two pathologists.[22,23] We found 76 cases of "negative for intraepithelial lesion or malignancy (NILM)," 28 of "low-grade SIL (LSIL)," 30 of "high-grade SIL (HSIL)," 11 of "atypical squamous cells of undetermined significance (ASC-US)," and 4 of "atypical squamous cells, cannot exclude HSIL (ASC-H)." ASC-H was excluded from the study because of a small number of available cases. The incidence of HSIL and ASC-US was higher in our subjects versus those reported previously[24]; this was probably due to a difference in the background of the population (a substantial number of subjects in the present study visited the hospital as they had some signs/symptoms or suspicious screening results). The average age of the 145 cases was 36 ± 13 years (range, 17–90 years), and no significant difference was observed among the four classes of diagnosis. The follow-up data were collected for 61 cases diagnosed as NILM (52 cases) and ASC-US (9 cases) at the first visit. During the follow-up period, 20 cases were found to be diagnosed either as ≥CIN1 by the histological examination or ≥LSIL by the cytological examination, and were classified into the progressed/discordant cases. It should be noted that the 20 cases included both false-negative cases at the first cytological diagnosis and cases with true biological progression of CIN. We retrospectively reviewed the cytology samples of the cases that were classified into the progressed/discordant cases to confirm the diagnosis. The follow-up periods were 5–1,278 days (median, 319 days) and the median of the follow-up interval was 101 days (from 12 to 722 days). The follow-up examinations were performed by the cytological and/or histological examinations based on clinical decisions. A total of 80% of the HSIL cases were diagnosed thus far and treated as CIN3 in the following biopsy/conization.

All the participants gave an informed consent and the study protocol was approved by the local ethics committee of the NHO Hamada Medical Center.

Immunocytochemistry

For immunostaining of p16, the CINtec Histology kit (Roche mtm laboratories AG, Heidelberg, Germany) was used according to the manufacturer's instructions. The

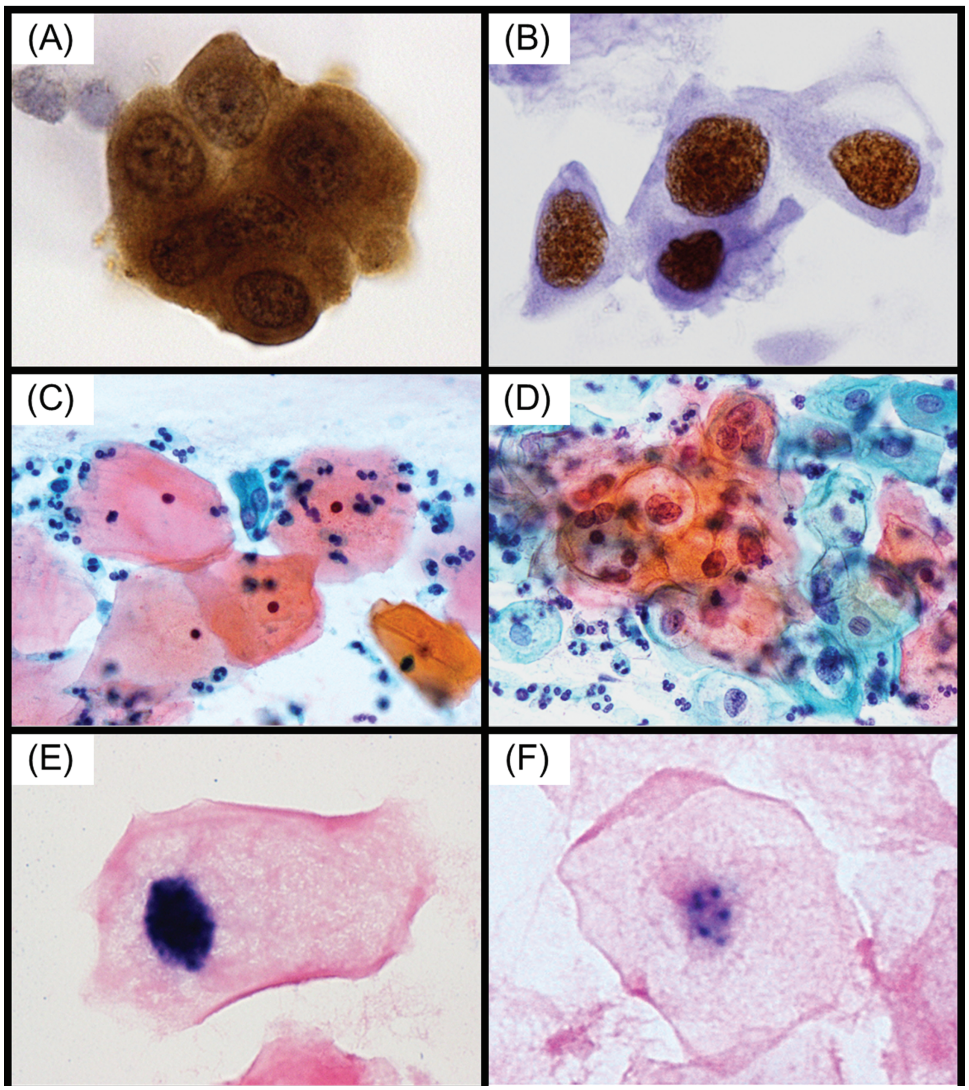

Fig. C-1. The cytological appearance of the conventional Papanicolou stain and the immunostaining for p16/p21, and the in situ hybridization for high-risk HPV. The epithelial cells positive for p16 (**A**) and for p21 (**B**) as well as the episomal (**E**), and the integrated (**F**) pattern of the in situ hybridization for high-risk HPV are shown. The cells diagnosed as NILM (**C**) and LSIL (**D**) by the conventional cytology.

primary antibody was a mouse anti-human $p16^{INK4a}$ antibody (clone E6H4™) that was included in the kit. For the staining of p21, the ChemMate ENVISION kit (DAKO A/S, Glostrup, Denmark) was used with a monoclonal mouse anti-human $p21^{WAF1/Cip1}$ antibody (clone SX118, 1:50 dilution, DAKO A/S) as the primary antibody. Immunostaining was performed on the Autostainer Plus (DAKO A/S).

Typical examples of the immunocytochemistry are shown in Fig. C-1. As reported previously, both the cytoplasm and the nucleus stained positively for p16 (Fig. C-1A), while only the nucleus stained for p21 (Fig. C-1B).[25] It should be noted that the normal epithelial cells may express p16 in a focal or patchy pattern during cellular cycling.[7] However, as the neoplastic cells show a stronger and diffuse pattern of p16 staining, one may distinguish the neoplastic cells from the normal cells.[26] In the liquid-based cytological material, we diagnosed p16-positive cells without any dysplastic changes (i.e., NILM) based on the cytological appearance of the cells (see Figs. C-1C and D) as well as on the staining pattern of p16. The cases with an uncertain diagnosis were re-evaluated through a close discussion between K.I. and M.N.

In Situ Hybridization

ISH for the HPV genome was performed using a commercial kit (ISH iVIEW Blue Plus Detection kit with

Table I. The Result of the Immunocytochemical Test for p16/p21 and the Genomic Tests for HPV in the Four Cytological Classes

	n	*p16* *Positives (%)*	*p21* *Positives (%)*	*p16 and p21* *Positives (%)*	*p16 or p21* *Positives (%)*	*Dot blot (hrHPV 14 types)* *Positives (%)*	*ISH (hrHPV 12 types)*	
							Positives (%)	*I>E (% to positives)*
NILM	76	14 (18%)	12 (16%)	3 (4%)	23 (30%)	20 (26%)	4 (5%)	1 (25%)
ASC-US	11	4 (36%)	3 (27%)	3 (27%)	4 (36%)	6 (55%)	5 (45%)	1 (20%)
LSIL	28	16 (57%)	8 (29%)	5 (18%)	19 (68%)	25 (89%)	23 (83%)	3 (13%)
HSIL	30	30 (100%)	21 (70%)	21 (70%)	30 (100%)	28 (93%)	29 (97%)	27 (93%)

All of the columns showed significant linear trends of increase in incidents of positive cases along with the progression in the cytological class. hrHPV: high-risk subtypes of Human Papillomavirus, ISH; in-situ hybridization, I>E; the integrated pattern predominant in the ISH.

INFORM HPV III Family 16 probe [C]; Ventana Medical Systems, Tucson, AZ) on a BenchMark LT automated slide-staining system (Ventana Medical Systems). The probe cocktail used in the ISH was for 12 high-risk HPVs (type 16, 18, 31, 33, 35, 39, 45, 51, 52, 56, 58, and 66).

The cells positively stained in the cytological specimen were classified into two different patterns: a diffuse episomal (E) pattern (Fig. C-1E) and a dotted integrated (I) pattern (Fig. C-1F).[17,19,20] On each cytological specimen, the positive cells were classified into the E or I patterns. Thereafter, each case was categorized into three groups: cases with no positive ISH signals, cases of the E pattern predominant (E≥I), and cases of the I pattern predominant (I>E).

HPV Genotyping by PCR-Reversed Dot Blotting

DNA was extracted from the residual cytological samples in ThinPrep PreservCyt Solution using a commercial kit (MagCore Genomic DNA Tissue kit, RBC Bioscience, Taipei, Taiwan) on the MagCore HF16 system (RBC Bioscience). Polymerase chain reaction (PCR) was performed using the 2720 Thermal Cycler (Applied Biosystems, Carlsbad, CA). Genotyping was performed with a HPV GenoArray Test kit (HybriBio, Hong Kong, China) on the HybriMax system (HybriBio), which can detect 14 high-risk genotypes (type 16, 18, 31, 33, 35, 39, 45, 51, 52, 56, 58, 59, 66, and 68), 6 low-risk genotypes (type 6, 11, 42, 43, 44, and CP8304), and one undetermined-risk genotype (type 53). Each of these dot-blotting membranes included one negative and one positive control blotting area, respectively.

Statistics

The contingency table analysis or Student's *t*-test was used as univariate analyses when it was appropriate. The multiple logistic regression analysis was employed when the effects of the immunostaining of p16 and p21 on the cytological diagnosis were evaluated under the adjustment of other confounding factors. The log-rank test and Cox proportional hazard model were applied to analyze the follow-up data. Statistical analyses were performed with JMP v. 10 (SAS Institute Inc., Cary, NC). $P < 0.05$ was considered to be statistically significant.

Results

p16/p21 Expression and HPV Infection in the Cytological Samples

Table I summarizes the results of the immunocytochemical test for p16 and p21, as well as the genomic tests for HPV in the 145 cytological specimens. The cases with a positive expression of p16 and p21 increased with the cytological grade (the linear trend was statistically significant, data not shown). Although substantial NILM and LSIL cases stained positively for either p16 (18 and 57%, respectively) or p21 (16 and 29%, respectively). It should be noted that the cases positive for both p16 and p21 were reduced greatly in the NILM and LSIL cases (4 and 18%, respectively), which was in contrast to the high positive rate in HSIL (70%). This implied that the double staining for p16 and p21 increased the specificity for HSIL. In fact, when the sensitivity, specificity, positive predictive value (PPV), and negative predictive value (NPV) were calculated to distinguish between HSIL and LSIL, the double staining for p16 and p21 improved the specificity and the PPV (Table II).

The results of the dot blotting and the ISH indicated that the positive rates of HPV were comparable between the two methods for the LSIL and HSIL cases. However, in NILM, the positive rate in the dot blotting was greater than that in ISH (26 and 5 %, respectively). This probably results from the much greater sensitivity of the reversed dot blotting due to the employment of PCR in this method. In the cases without a high-risk HPV infection, only 4 cases were positive for low- and undetermined-risk HPV alone in NILM, and the other 52 cases were negative for HPV. In contrast, in LSIL and HSIL, all the cases were infected with high-risk HPV that could be detected either by dot blotting or ISH. Approximately one half of the cases of ASC-US were infected with high-risk HPV detected by dot blotting or ISH. It is of interest that the I>E pattern prevailed in the HSIL cases (93%), while the E≥I pattern was mainly observed in the LSIL cases (100–13% = 87%).

The utility of the immunocytochemistry and the HPV genomic analyses were evaluated based on their sensitivity, specificity, PPV, and NPV. For the discrimination

Table II. The Sensitivity, Specificity, Positive Predictive Value, and Negative Predictive Value of the p16/p21 Immunocytochemistry and HPV Examination

	LSIL vs. NILM				*HSIL vs. LSIL*			
	Sens	*Spec*	*PPV*	*NPV*	*Sens*	*Spec*	*PPV*	*NPV*
Immunocytochemical tests								
p16 (+)	0.57	0.82	0.53	0.84	1.0	0.43	0.65	1.0
p21 (+)	0.29	0.84	0.40	0.76	0.70	0.71	0.72	0.69
p16 (+) or p21 (+)	0.68	0.70	0.45	0.85	1.0	0.32	0.61	1.0
p16 (+) and p21 (+)	0.18	0.96	0.60	0.76	0.70	0.82	0.81	0.72
Genomic tests for hrHPV								
Dot blotting positive (hrHPV 14 types)	0.89	0.74	0.50	0.92	0.93	0.11	0.54	0.63
I>E in the ISH for hrHPV 12 types	0.11	0.99	0.75	0.75	0.90	0.89	0.90	0.89

hrHPV, high-risk subtypes of Human Papillomavirus; I>E, the integrated pattern predominant; ISH, in-situ hybridization; Sens, sensitivity; Spec, specificity; PPV, positive predictive value; NPV, negative predictive value.
Immunocytochemical tests for p16 / p21 and genomic tests for hrHPV shown in bold letters indicate the best that discriminate either between LSIL and NILM, or between HSIL and LSIL.

between LSIL and HSIL, "p16 (+) and p21 (+)" and "I>E pattern by the ISH" were the best in the immunocytochemistry and the HPV genomic tests, respectively. On the other hand, for the discrimination between LSIL and NILM, "p16 (+) or p21 (+)" and "p16 (+)" were comparable with each other. In the following analyses, we showed the results using "p16 (+) or p21 (+)" as the best discriminator between LSIL and NILM. When "p16 (+)" was used instead, it gave basically the same results as those using "p16 (+) or p21 (+)" (data not shown). In the two HPV genomic tests, the dot blotting test was the best for the discrimination between LSIL and NILM. (shown in bold letters in Table II).

Multiple Logistic Regression Analysis

A further evaluation of the "best" four tests selected above (see Table II) was performed by multiple logistic regression analysis. Due to the cost and the time-consuming protocol for the genomic tests for HPV, it is ideal to substitute the immunostaining of p16 and p21 for the genomic tests. Hence, in model 1, the immunocytochemical examination was evaluated without the genomic tests for HPV, while, in model 2, the genomic tests were added to the analysis. Under an adjustment of the patients' age and the history of CIN, the immunocytochemistry for p16 and p21 was a significant discriminator of the cytological grade both between HSIL/LSIL and NILM, and between HSIL and LSIL/NILM. Furthermore, even in combination with the genomic tests for HPV, the immunocytochemistry was still an independent factor in discriminating the cytological grades (Table III).

Table III. Evaluation of the Usefulness of p16/p21 Immunocytochemistry on the Cytological Diagnosis With (Model 2) and Without (Model 1) the Genomic Tests for HPV

	$\beta \pm SE$	$\chi 2$	*P*	*OR [95% CI]*
(A) HSIL/LSIL vs. NILM				
Model 1				
p16 (+) or p21 (+)	1.3 ± 0.23	42.9	<0.0001	13.7 [5.9, 35.6]
Model 2				
p16 (+) or p21 (+)	1.27 ± 0.28	20.7	<0.0001	12.7 [4.5, 41.0]
hrHPV (+)	1.65 ± 0.31	29.9	<0.0001	27.2 [9.1, 99.6]
(B) HSIL vs. LSIL/NILM				
Model 1				
p16 (+) and p21 (+)	1.67 ± 0.27	37.7	<0.0001	28.1 [10.2, 87.0]
Model 2				
p16 (+) and p21 (+)	1.38 ± 0.50	7.6	0.006	15.7 [2.5, 146.0]
ISH (I>E)	2.76 ± 0.54	26.3	<0.0001	248 [40.2, 3290]

Effects of p16/p21 immunocytochemistry on the cytological diagnosis were evaluated under adjustment of age and history of CIN by multiple logistic regression.
The genomic tests for HPV were included in the model 2 while not in the model 1.
OR; odds ratio, CI; confidence interval, hrHPV: high-risk subtypes of Human Papillomavirus, I>E; the integrated pattern predominant.

A Follow-Up Study of NILM/ASC-US Cases

The analyses above indicated that the p21 and p16 expression in the cytological specimens was useful in the diagnosis of SIL. However, the most interesting issue in clinical practice is whether p21 and p16 immunostaining can provide useful information regarding the progression of the disease in NILM/ASC-US cases. In order to evaluate the utility of p16 and p21 immunocytochemistry, as well as the genomic tests for HPV in the prediction of the disease progression, we performed a prospective study in 61 NILM/ASC-US cases. We found a progression of the disease in 20 cases during the follow-up period, either by the cytological or by the histological examination (see Methods).

The follow-up cases are summarized in Table IV. The follow-up period was significantly longer in the cases without progression, which was natural because most of the NILM/ASC-US cases were followed up continuously until any progression was observed. The incidence of high-risk HPV was significantly greater in the progressed cases.

The four tests selected in Table II were examined to determine whether they could identify the cases with disease progression. As shown in Fig. 1, the log-rank test

indicated that the infection of high-risk HPV, as well as the cytological diagnosis (ASC-US vs. NILM), influenced the prognosis significantly ($P = 0.007$ and 0.002, respectively). On the other hand, the status of the p16 and p21 expression by immunocytochemistry did not achieve significance.

It was expected that the ASC-US cases had a greater risk for the progression to higher grades of CIN/SIL, and, thus, to evaluate the effects of p16/p21 staining on the prognosis accurately; such confounding factors were to be adjusted in a multivariate analysis. The Cox proportional hazard model confirmed the independent effects of the cytological diagnosis and high-risk HPV infection. In addition, the patients' age and the history of CIN had weak negative effects on the prognosis. The positive staining for p16 or p21 was not found to be an independent risk factor (Table V).

Table IV. Summary of 61 Follow-Up Cases of NILM/ASC-US

	Progressed/discordant		
	No	*Yes*	*P*
N	41	20	
Age, years	39 ± 13	35 ± 12	0.2
Follow-up, days	390 ± 2	95 ± 4	<0.0001
ASC-US, %	9.8	25.0	0.14
Positive history of CIN, %	48.8	25.0	0.07
hrHPV (+), %	26.8	65.0	0.004
p16 (+), %	19.5	25.0	0.7
p21 (+), %	14.6	30.0	0.16
p16 (+) or p21 (+), %	26.8	40.0	0.3
p16 (+) and p21 (+), %	7.3	15.0	0.4

hrHPV, high-risk subtypes of HPV.

Discussion

In this study, we evaluated the utility of the immunocytochemistry for p16 and p21 as well as for the two genomic tests for high-risk HPV (i.e., reversed dot blotting and ISH) in the cytological diagnosis of SIL. The results indicated that the immunocytochemistry for p16 and p21 might be useful markers for the diagnosis of SIL in the cytological examinations. In contrast to the immunocytochemistry for p16, which was positive in the early stages of SIL, p21 seemed to be positive in the higher grades of SIL (see Table I). This result was consistent with some of the previous observations,[27,28] and may be reasonable because p21 is a CDK inhibitor that is activated directly by p53.[3] Hence, the positive staining for p21 gave a substantial improvement in the sensitivity and the specificity of the discrimination between LSIL and HSIL, although the I>E pattern in ISH gave the best discrimination (see

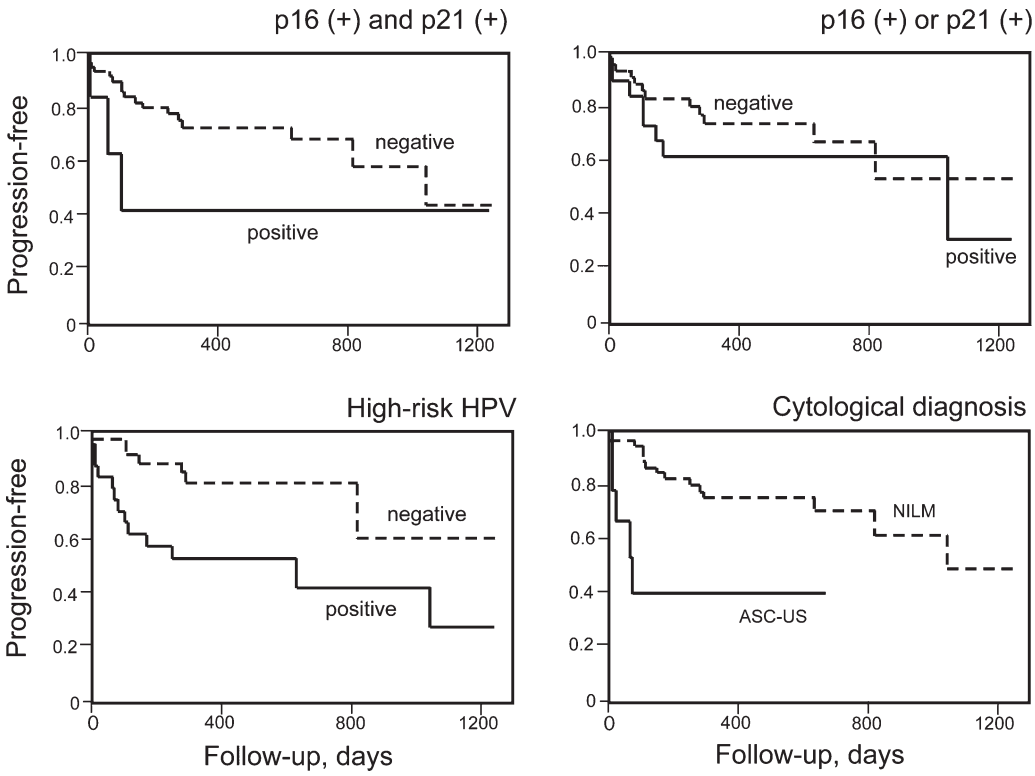

Fig. 1. The prospective evaluation of the four diagnostic factors in 61 NILM/ASC-US cases. The immunocytochemistry [p16 (+) and/or p21 (+)], the reversed dot blotting analysis for high-risk HPV and the cytological diagnosis were evaluated by Kaplan-Meier method. The latter two showed significant effects on the progression of SIL by the log-rank test [the dot blotting test for high-risk HPV; $P = 0.007$, the cytological diagnosis; $P = 0.002$].

Table V. Evaluation of Prognostic Factors for the SIL/CIN Progression in 61 NILM/ASC-US Cases

	$\beta \pm SE$	χ^2	*P*	*RR [95% CI]*
Age	−0.05 ± 0.03	4.6	0.03	0.95 [0.90, 1.00]
Diagnosis (ASC-US)	0.89 ± 0.31	7.2	0.007	6.0 [1.7, 19.5]
History of CIN (+)	−0.59 ± 0.30	4.3	0.04	0.3 [0.09, 0.9]
hrHPV (+)	0.63 ± 0.25	6.7	0.001	3.5 [1.3, 9.8]
p16 (+) or p21 (+)	0.07 ± 0.25	0.09	0.8	0.9 [0.3, 2.3]

Independent effects of factors listed were evaluated by Cox proportional hazard model.
RR, relative risk; CI, confidence interval; hrHPV, high-risk subtypes of HPV.

Table II). However, for the discrimination between LSIL and NILM, the immunocytochemistry for p21 seemed less useful. In the earlier stage of SIL/CIN, the HPV E7 proteins inactivate the RB protein, which may then induce a compensatory overexpression of p16, while p21 may be expressed only after p53 is fully activated to prevent any carcinogenesis in the later stage.[29]

As the immunocytochemistry alone produced significant effects in the discrimination of SIL, this examination may help in the routine clinical diagnosis even without any information pertaining to HPV infections. However, as indicated with the odds ratios (OR) in Table III, the genomic examinations for HPV infection were still superior to the immunostaining of p16 and p21. Therefore, it is more prudent to say that the immunocytochemistry for p16 and p21 could not yet be substituted for the genomic examination of HPV. As the procedure was much simpler for the immunocytochemistry, it may be the second best supportive method.

It is of interest that even with the HPV genome tests, the p16/p21 immunocytochemistry was still informative with respect to the diagnosis of SILs. In fact, the receiver operating characteristics analysis in the logistic regression showed that, in the discrimination between LSIL/HSIL and NILM, the area under the curve (AUC) for the dot blotting alone was 0.84, which increased to 0.91 when the information on the immunostaining of p16/p21 was added. In the case between HSIL and LSIL/NILM, the I>E pattern in ISH gave as high an AUC as 0.95, and the addition of the immunocytochemistry gave a little increase in the AUC. This observation suggested that, in the differential diagnosis between HSIL/LSIL and NILM, the immunocytochemistry for p16/p21 might improve the diagnosis when it was performed with the dot-blotting test for HPV.

When the application of immunocytochemistry to the practical cytological examination is considered, it is desirable that the information is useful to predict the prognosis. The results of the prospective evaluation indicated that the immunocytochemistry did not add significant information to the prediction made via the genome analysis of HPV and the cytological diagnosis (see Fig. 1 and Table V). However, as only 6 of the 61 cases were positive both for p16 and p21, it is necessary to collect more cases to obtain a more conclusive result.

This study has some limitations. Firstly, in ISH, only a few cells were positively stained in some of the cytological samples, which might impose some uncertainty on the differentiation between the I>E and the E≥I patterns. In such cases, the abnormal cells were possibly few in the original blushed samples. However, the sample preparation used in this study might affect the recovery of the cells because the ThinPrep processor was not used in the preparation of the liquid-based samples.[30,31] In spite of this limitation, as the positive rates of the I>E in different SIL grades in the present study were consistent with those in the previous reports,[17,19,20] the I>E and E≥I patterns in this study may still be useful as a supportive method for the diagnosis.

Second, in a follow-up study, it was practically impossible to distinguish cases that were a false negative at the first diagnosis from cases with a true biological progression. However, we believe that there is little practical significance to separate the two in a clinical setting; it is important to identify cases that need a careful follow-up regardless of the reason for the follow-up. Exclusion of false positive cases may be possible in a future study in which a larger cohort will be followed for a longer observation period.

In general, however, differentiation of cases with true progression from those with potential regression is important in clinical practice.[32] Some reports suggested the significance of patients' age [the high rate of regression recorded in the patients under the age of 30[33]], and of the histological diagnosis and the natural history of CIN [cases of CIN2 showed a greater rate of regression than those of CIN3[34]]. In this study, as we rather focused on the progression to the lower level of SIL diagnosed by the cytological examination, only three and two of the 20 cases with progression were confirmed to be CIN2 and 3 by the histological examination, respectively. Evaluation of factors influencing the progression/regression may be a subject of future investigation.

Recently, the screening guidelines for the early detection of CINs were published by the American Cancer Society, American Society for Colposcopy and Cervical Pathology, and American Society for Clinical Pathology.[35] This article pointed out that the HPV genomic tests were useful in the prediction of CIN progression, but we need to apply them carefully because of the lower specificity, which might cause unnecessary 'anxiety' due to false positive results.[35] In this study, five of the nine ASC-US and eight of the 52 NILM cases were found to have "progressed" in their follow-up period, and it should be noted that all of them were positive for high-risk HPV, which confirmed the utility of the HPV genomic

tests in predicting cases that would progress to higher grades of CINs. Furthermore, the I>E pattern was a good indicator of higher grades of SIL (Tables II and III), thus implying that the ISH test is preferable to other HPV genomic tests, such as the dot blotting to detect CINs that needs immediate treatment. In spite of this, it is difficult to introduce the ISH test in routine examinations due to the cost and the laborious procedure. By contrast, the immunocytochemistry of p16 and p21 is a method that is more feasible in most of the clinical laboratories. The present study showed that the positive staining, for p16 and p21, was another good marker to distinguish higher grade SIL (Tables II and III). An additional analysis indicated that the sensitivity and specificity of 'double positive for p16 and p21' predicting the I>E in the ISH were 62% (21/34) and 90% (103/115), respectively, and PPV and NPV were 64% (21/33) and 89% (103/116), respectively. These results suggested that, even in the HPV-positive cases, HPV might not be integrated into the host genome when either p16 or p21 was negative, which might indicate a lower risk for progression.

Although this study failed to establish the superiority of the immunostaining alone versus the HPV genomic tests in the screening, the combination of the immunostaining and HPV genomic tests may be useful in routine examinations, thus providing a better screening strategy from the aspect of 'the fundamental goal of cervical cancer screening' that is "to prevent morbidity and mortality from cervical cancer" and "to avoid the detection and unnecessary treatment of transient HPV infection."[35] Further studies are essential to improve the sensitivity and the PPV to establish the clinical significance of the p16/p21 immunostaining in the prediction of the ISH patterns.

In conclusion, this study indicated that the immunostaining for p16/p21 in the cytological specimens may provide additional supportive information in the diagnosis of SIL. The significance of the immunostaining of p16/p21 in the prediction of the prognosis in the cases at an early stage of HPV infection needs to be established in a future study using a larger population.

References

1. Zur Hausen H. Papillomaviruses and cancer: From basic studies to clinical application. Nat Rev Cancer 2002;2:342–350.
2. Klaes R, Woerner SM, Ridder R, et al. Detection of high-risk cervical intraepithelial neoplasia and cervical cancer by amplification of transcripts derived from integrated papillomavirus oncogenes. Cancer Res 1999;59:6132–6136.
3. Kim YT, Zhao M. Aberrant cell cycle regulation in cervical carcinoma. Yonsei Med J 2005;46:597–613.
4. Bahnassy AA, Zekri AR, Alam El-Din HM, et al. The role of cyclins and cyclins inhibitors in the multistep process of HPV-associated cervical carcinoma. J Egypt Natl Canc Inst 2006;18:292–301.
5. Klaes R, Friedrich T, Spitkovsky D, et al. Overexpression of p16 ^{INK4a} as a specific marker for dysplastic and neoplastic epithelial cells of the cervix uteri. Int J Cancer 2001;92:276–284.
6. Dehn D, Torkko KC, Shroyer KR. Human papillomavirus testing and molecular markers of cervical dysplasia and carcinoma. Cancer 2007;111:1–14.
7. Benevolo M, Vocaturo A, Mottolese M, et al. Clinical role of p16^{INK4a} expression in liquid-based cervical cytology: Correlation with HPV testing and histologic diagnosis. Am J Clin Pathol 2008;129:606–612.
8. Monsonego J, Pollini G, Evrard MJ, et al. p16 ^{INK4a} immunocytochemistry in liquid-based cytology samples in equivocal Pap smears: Added value in management of women with equivocal Pap smear. Acta Cytol 2007;51:755–766.
9. Huang LW, Chou YY, Chao SL, Chen TJ, Lee TT. p53 and p21 expression in precancerous lesions and carcinomas of the uterine cervix: Overexpression of p53 predicts poor disease outcome. Gynecol Oncol 2001;83:348–354.
10. Troncone G, Martinez JC, Palombini L, et al. Immunohistochemical expression of mdm2 and p21^{WAF1} in invasive cervical cancer: Correlation with p53 protein and high risk HPV infection. J Clin Pathol 1998;51:754–760.
11. Abbas T, Dutta A. p21 in cancer: Intricate networks and multiple activities. Nat Rev Cancer 2009;9:400–414.
12. Melsheimer P, Vinokurova S, Wentzensen N, Bastert G, von Knebel Doeberitz M. DNA aneuploidy and integration of human papillomavirus type 16 E6/E7 oncogenes in intraepithelial neoplasia and invasive squamous cell carcinoma of the cervix uteri. Clin Cancer Res 2004;10:3059–3063.
13. Wentzensen N, Vinokurova S, von Knebel Doeberitz M. Systematic review of genomic integration sites of human papillomavirus genomes in epithelial dysplasia and invasive cancer of the female lower genital tract. Cancer Res 2004;64:3878–3884.
14. Pett M, Coleman N. Integration of high-risk human papillomavirus: A key event in cervical carcinogenesis? J Pathol 2007;212:356–367.
15. Raybould R, Fiander A, Hibbitts S. Human papillomavirus integration and its role in cervical malignant progression. Open Clin Canc J 2011;5:1–7.
16. Cooper K, Herrington CS, Stickland JE, Evans MF, McGee JO. Episomal and integrated human papillomavirus in cervical neoplasia shown by non-isotopic in situ hybridisation. J Clin Pathol 1991;44: 990–996.
17. Evans MF, Mount SL, Beatty BG, Cooper K. Biotinyl-tyramide-based in situ hybridization signal patterns distinguish human papillomavirus type and grade of cervical intraepithelial neoplasia. Mod Pathol 2002;15:1339–1347.
18. Guo M, Gong Y, Deavers M, et al. Evaluation of a commercialized in situ hybridization assay for detecting human papillomavirus DNA in tissue specimens from patients with cervical intraepithelial neoplasia and cervical carcinoma. J Clin Microbiol 2008;46:274–280.
19. Guo M, Patel SJ, Chovanec M, et al. A human papillomavirus testing system in women with abnormal Pap results: A comparison study with follow-up biopsies. Acta Cytol 2007;51:749–754.
20. Ho CM, Lee BH, Chang SF, et al. Clinical significance of signal pattern of high-risk human papillomavirus using a novel fluorescence in situ hybridization assay in cervical cytology. Clin Microbiol Infect 2011;17:386–394.
21. Bigras G, Rieder MA, Lambercy JM, et al. Keeping collecting device in liquid medium is mandatory to ensure optimized liquid-based cervical cytologic sampling. J Low Genit Tract Dis 2003;7:168–174.
22. Apgar BS, Brotzman G. Management of cervical cytologic abnormalities. Am Fam Physician 2004;70:1905–1916.
23. Wright TC, Jr, Massad LS, Dunton CJ, Spitzer M, Wilkinson EJ, Solomon D; 2006 American Society for Colposcopy and Cervical Pathology-sponsored Consensus Conference. 2006 consensus

guidelines for the management of women with abnormal cervical cancer screening tests. Am J Obstet Gynecol 2007;197:346–355.

24. Siebers AG, Klinkhamer PJ, Grefte JM, et al. Comparison of liquid-based cytology with conventional cytology for detection of cervical cancer precursors: a randomized controlled trial. JAMA 2009;302:1757–1764.
25. Moore GD, Lear SC, Wills-Frank LA, Martin AW, Snyder JW, Helm CW. Differential expression of cdk inhibitors p16, p21cip1, p27kip1, and cyclin E in cervical cytological smears prepared by the ThinPrep method. Diagn Cytopathol 2005;32:82–87.
26. Denton KJ, Bergeron C, Klement P, Trunk MJ, Keller T, Ridder R; European CINtec Cytology Study Group. The sensitivity and specificity of p16 ^{INK4a} cytology vs HPV testing for detecting high-grade cervical disease in the triage of ASC-US and LSIL pap cytology results. Am J Clin Pathol 2010;134:12–21.
27. Tsoumpou I, Arbyn M, Kyrgiou M, et al. p16 ^{INK4a} immunostaining in cytological and histological specimens from the uterine cervix: A systematic review and meta-analysis. Cancer Treat Rev 2009;35:210–220.
28. Bae DS, Cho SB, Kim YJ, et al. Aberrant expression of cyclin D1 is associated with poor prognosis in early stage cervical cancer of the uterus. Gynecol Oncol 2001;81:341–347.
29. Cheung TH, Lo KW, Yu MM, et al. Aberrant expression of $p21^{WAF1/CIP1}$ and $p27^{KIP1}$ in cervical carcinoma. Cancer Lett 2001;172:93–98.
30. Song LH, Goh ES, Phang LC, Poh WT, Tay SK. Technical aspect of ThinPrep. Singapore Med J 2000;41:575–578.
31. Grace A, McBrearty P, Troost S, Thornhill M, Kay E, Leader M. Comparative study: Conventional cervical and ThinPrep® Pap tests in a routine clinical setting. Cytopathology 2002;13:200–205.
32. Syrjänen K, Kataja V, Yliskoski M, Chang F, Syrjänen S, Saarikoski S. Natural history of cervical human papillomavirus lesions does not substantiate the biologic relevance of the Bethesda System. Obstet Gynecol 1992;79:675–682.
33. Ostör AG. Natural history of cervical intraepithelial neoplasia: A critical review. Int J Gynecol Pathol 1993;12:186–192.
34. Moscicki AB, Shiboski S, Hills NK, et al. Regression of low-grade squamous intra-epithelial lesions in young women. Lancet 2004;364:1678–83.
35. Saslow D, Solomon D, Lawson HW, et al. American Cancer Society, American Society for Colposcopy and Cervical Pathology, and American Society for Clinical Pathology screening guidelines for the prevention and early detection of cervical cancer. Am J Clin Pathol 2012;137:516–542.